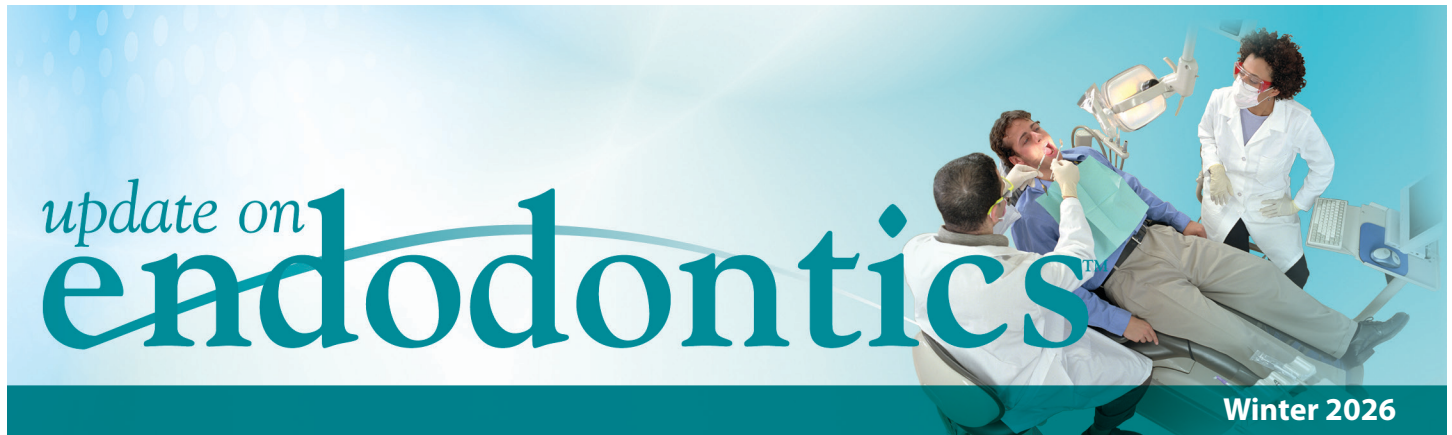

A Professional Courtesy of:



DR. SIMONA PESUN • DR. RODRIGO SANCHES CUNHA
DR. MICHAEL RODILLO • DR. ALDO DEL CARPIO PEROCHENA

271 Madison St. • Winnipeg, Manitoba R3J 1H6
Ph: 204.808.0030 • Fax: 204.808.0031
Email: welcome@prairieendo.ca • www.prairieendo.ca



Surface Roughness After Apicoectomy

When nonsurgical endodontic treatment or retreatment has failed to resolve persistent apical periodontitis, the next step is an apicoectomy, which involves removing the affected root apex. The use of ultrasonic tips has led to success rates of >90% for endodontic microsurgery. However, an apicoectomy requires the use of several different types of instruments, resulting in varying levels of root surface smoothness. Ultrasonic tips leave a rougher surface than that obtained using burs that can affect the proliferation and migration of cells toward the synthesis of a calcified bone matrix, a process critical for proper tissue repair.

Little literature exists that evaluates how the roughness of the surface after the use of ultrasonic tips for an apicoectomy influences cellular attachment. To fill this hole in the knowledge, Pereira et al from the State University of Campinas, Brazil, compared apicoectomies using ultrasonic tips or a high-speed carbide bur for the time required for the resection, the dentinal surface roughness and the viability of the attached cells on the dentinal surfaces.

The researchers performed endodontic treatment on 64 single-rooted teeth extracted as part of orthodontic treatment. The treated teeth were then divided into 4 groups and underwent apicoectomies using 4 different tools:

- Zekrya bur using a high-speed handpiece
- Blade Sonic ultrasonic tip activated by a piezoelectric ultrasonic device at 60% power
- OT12 ultrasonic tip activated by a piezosurgical ultrasonic device at the “cortical” power setting
- Zekrya bur followed by multiblade burs to obtain surface smoothness (control)

Inside this issue:

- Permanent Tooth Intrusion Outcomes
- Irrigants' Role in Pre-endodontic Restorations
- TMD and Endodontic Treatment

Postoperatively, 10 of the teeth from each group were analyzed for surface roughness and then scored from 0 (smooth surface) to 3 (severe roughness). The remaining 6 teeth from each group were exposed to human primary gingival fibroblasts, and the viability of the cells that attached to the root ends was evaluated.

The apicoectomy was completed more quickly using the OT12 ultrasonic tip than using the Blade Sonic tip. The OT12 ultrasonic tip also created significantly greater surface roughness than did the other tools tested. Cell attachment at 6 hours for the Zekrya bur and the Blade Sonic ultrasonic tip groups was inferior to that of the control group; cell attachment for the Zekrya bur group continued to be inferior to that of the control group at 24 and 48 hours. In contrast, cell attachment for the OT12 and Blade Sonic ultrasonic tips was significantly increased compared with that of the control group at 48 hours.

Conclusion

Received opinion since the 1990s has been that an apicoectomy should provide a flat and smooth surface to minimize debris deposition and biofilm adhesion. In implantology, researchers have found that a rough surface promotes cell migration, osteoblastic differentiation and osteogenesis, along with the activation of platelets, growth factors and cytokines. In periodontics, researchers have reported that a rough surface enhances biological responses that enable periodontal cell attachment, differentiation and proliferation.

The current study demonstrated that a rougher surface increases the attachment of human primary gingival fibroblasts. Further studies are needed to determine whether the benefits of a rough surface outweigh the potential drawbacks of debris accumulation and biofilm formation.

Pereira LSAB, Pereira LAP, Bombarda GF, et al. Dentinal surface roughness after apicoectomy improves cell attachment. J Endod 2025;51:948-953.

Permanent Tooth Intrusion Outcomes

Although uncommon, intrusion—the axial displacement of a tooth into the socket—is one of the most severe dental injuries damaging the alveolar bone, periodontal ligament, cementum and pulp. Replacement resorption, also known as ankylosis, may result from the damage to the periodontal ligament, with the root structure replaced by bony tissue, can lead to infrapositioned teeth that disrupt arch development, causing space loss, bony defects and discrepan-

cies of the gingival contour. In growing patients, ankylosed teeth need to be decoronated before the tooth becomes severely infrapositioned.

Dental intrusion's severance of blood vessels entering the apical foramen can lead to the loss of pulpal vitality. In more mature roots, greater likelihood exists for pulp necrosis, and pulp revascularization is unlikely; however, teeth with immature apices have a greater chance of revascularization. Limited data exist for pulp survival and the time until the pulp in intruded young permanent teeth becomes necrotic. Schweiger et al from Ohio State University studied the risk of pulpal necrosis, ankylosis and tooth loss in intruded permanent teeth and their association with the degree of intrusion, stage of root development and initial treatment administered.

The retrospective chart review involved patients with intrusion of a permanent tooth who presented at a large urban children's hospital over a 9-year period. Most of the 77 patients were ≤11 years of age (range, 6 to 17 years), with a median age of 8 years. The 112 teeth included in the study were classified

Table 1. Survival probability of intruded teeth for pulp vitality (n = 107), ankylosis (n = 112) and tooth survival (n = 112) at 1 and 2 years postinjury.

	Root development		Degree of intrusion			Primary treatment	
	Immature	Mature	1–3 mm	4–6 mm	>6 mm	Spontaneous	Surgical
Pulp vitality							
at 1 year	67%	11%	59%	39%	17%	59%	13%
at 2 years	63%	11%	59%	20%	17%	55%	13%
Ankylosis							
at 1 year	95%	72%	94%	91%	71%	96%	69%
at 2 years	91%	47%	83%	76%	55%	92%	42%
Tooth loss							
at 1 year	87%	80%	97%	65%	78%	87%	80%
at 2 years	87%	55%	97%	65%	57%	87%	55%

as either immature or mature based on the stage of root formation. Based on clinical and radiographic findings, degree of intrusion was categorized as mild (1 to 3 mm), moderate (4 to 6 mm) or severe (>6 mm). The time to a diagnosis of ankylosis, the time to a diagnosis of pulp necrosis and the time to when the tooth was extracted, decoronated or underwent pulpectomy (if applicable) were noted.

At the end of a 2-year follow-up, 16% of the teeth were ankylosed, 55% had necrotic pulp and 20% were lost (decoronated or extracted). The probability of ankylosis increased in mature teeth, severely intruded teeth and surgically repositioned teeth. There was also an increase in loss of these teeth over the study period (Table 1). Mean survival times for teeth diagnosed with pulp necrosis and ankylosis were significantly worse for mature teeth, teeth with greater degrees of intrusion and teeth that required surgical treatment; similar results were found for lost teeth, although the difference between teeth with immature and mature roots did not quite reach significance.

Conclusion

The study findings showed that the risk of ankylosis, pulp necrosis and tooth loss increased in permanent teeth with advanced root development, a greater degree of intrusion and surgical repositioning. Pulp necrosis was associated with mature root development, and tooth loss was associated with severity of intrusion; however, even with severe intrusion, >70% of the teeth did not ankylose, while the rate for less severe intrusion was >90%.

Schweiger BM, Tang H, Townsend JA, et al. Outcomes of permanent tooth intrusion: pulp necrosis, ankylosis and tooth loss. *Dent Traumatol* 2025;doi:10.1111/edt.70005.

Irrigants' Role in Pre-endodontic Restorations

The elimination and prevention of infection within the root canal system is fundamental to disinfecting the root canal, enhancing cleanliness, eliminating bacteria and removing the smear layer. The gold standard among irrigants remains sodium hypochlorite (NaOCl), either alone or augmented by the addition of ethylenediaminetetraacetic acid (EDTA), citric acid or chlorhexidine.

A pre-endodontic restoration is often undertaken before proceeding with root canal treatment in teeth with significant coronal structure loss. An adhesive resin composite, the most commonly used material for pre-endodontic restorations, may degrade after prolonged exposure to irrigant solutions used in endodontic treatment, diminishing the composite material's adhesion properties. Moreover, irrigant solutions may affect the dental matrix metallo-proteinases, further compromising the stability of adhesive restorations.

Francinelli et al from the University of Brescia, Italy, undertook a study to evaluate the influence of different irrigating solutions on microshear bond strength (μ SBS) and the dentinal enzymatic activity of pre-endodontic adhesive resin compound restorations after 24 hours or after 10,000 thermocycles. Sixteen extracted human molars were cut 1 mm above the cemento-enamel junction (CEJ) and had their roots removed, leaving a tooth sample with an enamel portion close to the CEJ and deep dentin. The specimens were ground until a flat enamel and dentin surface was formed, and a

smear layer was created; then a resin composite restoration was placed in each specimen, mimicking a pre-endodontic restoration. Four groups were created based on the irrigation protocol followed:

- no irrigation (control)
- 5.25% NaOCl for 10 minutes and a final water rinse
- 5.25% NaOCl for 10 minutes and a final 2% chlorhexidine rinse for 2 minutes
- 5.25% NaOCl for 10 minutes and a final EDTA rinse for 2 minutes

Half the specimens in each group were stored in artificial saliva at 37°C overnight; the other half were subjected to 10,000 thermocycles, with a dwell time of 30 seconds at 5°C to 55°C. Following the storage time or thermocycling, all specimens underwent μ SBS testing.

After overnight storage, the group irrigated with EDTA demonstrated bond strength significantly higher than that of each of the other groups, none of which demonstrated any significant differences among each other. Thermocycling significantly reduced the bond strength of all groups, with no significant differences noted between the groups. Enzymatic activity was significantly greater after overnight storage for the group irrigated with NaOCl and water, while the EDTA group showed no difference from the control group. After thermocycling, the NaOCl and water group continued to exhibit the highest overall values, while the chlorhexidine and EDTA groups exhibited lower, comparable values.

Conclusion

The results of this study showed that although the choice of irrigant had a

significant impact on the immediate adhesive properties, any difference disappeared over time. However, the addition of chlorhexidine or EDTA to NaOCl decreased enzymatic activity, which should aid in preserving the pre-endodontic resin composite reconstruction of the interproximal wall for the final restoration.

Francinelli J, Mazzitelli C, Josic U, et al. Root canal irrigants and their role in the adhesion of pre-endodontic restorations. Clin Oral Investig 2025;doi:10.1007/s00784-025-06421-2.

TMD and Endodontic Treatment

Chronic dentoalveolar and orofacial pain presents a diagnostic challenge due to the potential for overlapping symptoms and the simultaneous existence of multiple types of chronic and/or acute odontogenic and nonodontogenic pain. Although in most situations temporomandibular disorder (TMD) does not exacerbate odontogenic pain, in patients reporting persistent pain after endodontic therapy, the source of the pain, either in part or entire, has been identified as TMD.

Overlapping symptoms of dental and orofacial pain may result in misdiagnosis leading to unnecessary endodontic procedures, which often result in postendodontic pain even when no persistence of infection exists. Signorelli et al from the Federal University of Uberlândia, Brazil, conducted an observational retrospective cohort study to determine the prevalence of endodontically treated teeth on the same side as pain complaints from patients attending a dental school TMD clinic.

The 85 patients (70 women) had been seen at a university TMD and pain clinic over a period of 17 months. Each received a diagnosis of TMD following the criteria of the Diagnostic Criteria for Temporomandibular Disorders. Demographic data, medical history, side of referred facial pain, medication use and classification of TMD (muscle pain, joint pain, mixed pain) were extracted from medical records. The numbers of endodontically treated teeth, extracted teeth and implants on each side of the mouth were determined by the analysis of radiographic images.

TMD associated with muscle pain was diagnosed in 40 patients, mixed pain in 34 patients and joint pain in 11 patients. From the entire pool, 58.8% of the patients had ≥ 1 endodontically treated tooth on the side with pain, while 71.8% of patients had no endodontically treated teeth on the side without pain; the difference was significant (Figure 1). A significant association was found between the number of endodontically treated teeth and both muscle TMD and mixed TMD, although not for joint TMD.

Conclusion

The results of this study underline the need for an accurate diagnosis. Unlike TMD pain, endodontic disease pain is predominantly inflammatory and secondary to external or internal pathologies; common etiologies include dental caries, trauma and operative dental procedures. On the other hand, the etiology of TMD is multifactorial,

Distribution of endodontically treated teeth on pain vs nonpain side

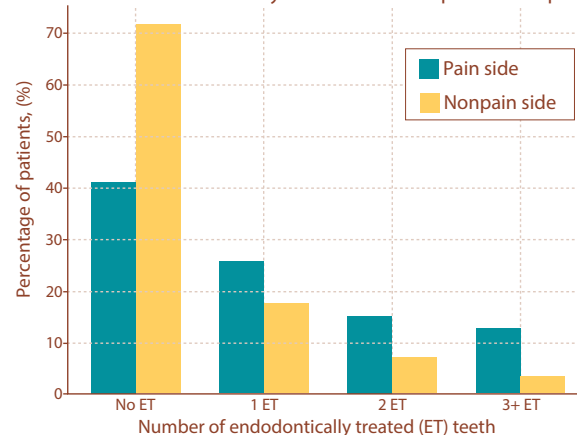


Figure 1. Distribution of endodontically treated teeth.

with pain resulting from parafunctional habits, repetitive microtraumas and direct or indirect trauma. In this study, 72% of patients presented with anxiety and depression, in line with previous studies that have shown that up to 75% of patients with TMD show psychological issues. These findings suggest that a psychological screening may be helpful in distinguishing endodontic pain from TMD-related pain.

Signorelli NSM, Moura CCG, Borges RF, et al. Prevalence of endodontically treated teeth in patients undergoing treatment for painful temporomandibular disorders: an observational study. J Endod 2025;51:890-897.

In the next issue:

- Coronal restoration on periapical healing and tooth survival
- Posttreatment apical periodontitis
- Pulpal deterioration after restorative procedures

Do you or your staff have any questions or comments about **Update on Endodontics**? Please call or write our office. We would be happy to hear from you. ©2026